

## **SURGICAL ASPECTS OF RENAL TRANSPLANTATION**

Mohammad Ayaz Hossain<sup>1</sup>, Radhika Chadha<sup>2</sup>, Atul Bagul<sup>3</sup>, Reza Motallebzadeh<sup>4,5</sup>

1- Department of Transplant Surgery, Cambridge University Hospital, Cambridge

2- Department of Academic Surgery, Oxford University Hospital, Oxford

3- Department of Renal Transplantation, Leicester General Hospital, Leicester

4- Department of Nephrology & Transplantation, Royal Free Hospital, London

5- Division of Surgery and Interventional Sciences; Centre for Transplantation, Department of Renal Medicine; and Institute of Immunity and Transplantation, University College London, London.

**Keywords:** Renal artery anastomosis, venous anastomosis, ureteric implantation techniques, implantation, Carrel patch, update

## CONTENTS

<b>INTRODUCTION</b>	<b>4</b>
<b>PRE OPERATIVE WORK UP</b>	<b>6</b>
Living kidney donation	6
Recipient	8
<b>SURGICAL TECHNIQUE</b>	<b>12</b>
Deceased donor procurement	12
<b>LIVE DONOR NEPHRECTOMY</b>	<b>15</b>
Laparoscopic Hand Assisted Donor Nephrectomy	17
Laparoscopic Retroperitoneal Donor Nephrectomy	19
Fully Laparoscopic Donor Nephrectomy	20
Open Retroperitoneal Nephrectomy	21
Robotic Donor Nephrectomy	<u>2322</u>
Complications	24
<b>RECIPIENT IMPLANTATION</b>	<b>25</b>
Implantation site	<u>2625</u>
Venous Anastomoses	28
Arterial Anastomoses	30
Reperfusion	33
Ureteric Implantation	34
Wound closure	37
Multiple Graft Implantation	37
<b>COMPLICATIONS OF RENAL TRANSPLANTATION</b>	<b>39</b>
Wound complications	39
Arterial	39
Venous	41
Ureteric complications	41

**Lymphocoele formation**

**42**

**DISCUSSION**

**43**

**REFERENCES**

**44**

## Introduction

Kidney transplantation has been the definitive treatment for end stage renal disease for the last 70 years. The fundamental principles of vascular anastomoses have been developed over the last one hundred years following the first recorded attempt at renal transplantation in 1902 in which a carotid to renal artery anastomosis was successfully accomplished. The use of the iliac vein and artery for renal transplantation, as pioneered by French surgeon Alex Carrel, still provides the foundations of the anastomotic technique utilised today (1,2). More recent advances in the field include the use of alternative vessels for anastomosis, variation in implantation site, performing the operation as part of a multi-visceral procedure and the use of suboptimal grafts.

Current research efforts focus on the non-surgical components of organ transplantation: tolerance-inducing protocols requiring little or no immunosuppression, organ procurement, preservation and machine perfusion as well as tissue matching. This drive has enabled renal allotransplantation to become the definitive treatment for end-stage renal disease over the last 70 years with one-year survival rates of allografted kidneys from living-related and deceased donors approaching 95% and 91% respectively (1). However, long-term graft survival outcomes remain less impressive, with chronic rejection and death with a functioning graft being the leading causes of late loss of renal allografts (more than one year after transplantation), resulting in an annual rate of loss of 3-5% (2, 3). The ongoing demand for kidney transplantation is therefore exacerbated by graft failure and the need for re-transplantation (4, 5).

Between 1960 and 1980 the estimated incidence for graft loss from surgical complications was 20%. Rates have dropped significantly since then but early detection, diagnosis and management of surgical complications are critical to further reduce patient morbidity, and potentially mortality, through graft loss. Surgical complications may be classified as under two broad categories: vascular (e.g. arterial

and venous thrombosis, renal artery stenosis, lymphocele and haemorrhage) and urologic (e.g. ureteral obstruction, vesicoureteral reflux, urinary leak). This chapter provides an overview of the existing surgical techniques employed in the field of kidney donation and transplantation along with some of the proposed updates to these procedures.

## Pre operative work up

### *Living kidney donation*

The options for live kidney donation in the UK have expanded over the last 10 years. Alongside the known related or unrelated direct and paired donation, altruistic donation, with or without direction, has seen an increase in incidence. The surgical work up for each donor remains the same and ~~ever more~~ it is increasingly apparent that the need for short and long term follow up after donor nephrectomy should be prioritised. Patients are counselled for the risk of hypertension as well as the development of end stage renal disease, which at 0.9% still remains substantially lower than that of the 3.2% risk in the general population (6, 7).

Identification of ~~risk during surgery~~ peri-operative risks should commence like with any elective procedure, with the donor health and medical history. Significant comorbidities contraindicate donation. Uncontrolled hypertension and diabetes with their associated risk to kidney function are also contraindicated given the increased risk of end stage diabetic nephropathy at 5 years being in the region of 25% (8). The associated risk of hypertension not only ~~incorporates~~ affects the anaesthetic risk but also the theoretical risk of hyperfiltration following nephrectomy leading to hyperalbuminuria and progressive glomerulopathy.

Malignancy and infection in the history of the donor does not absolutely contraindicate donation, but every effort must be made to exclude recurrent disease, mitigate risk and prevent transmission to the recipient.

Another often considered and subsequently managed risk is obesity. Worldwide rates of obesity are increasing, and the boundaries of acceptability of donor are widening. The widespread, almost, standard use of laparoscopic techniques over open, have enabled donors with BMIs of up to 35 kg/m<sup>2</sup> to be routinely considered for donation. That being said there is a greater risk of post-operative morbidity in the obese (9), and careful pre-operative assessment to exclude cardiovascular, respiratory and kidney disease is advised. Of note, obesity is now recognised as an independent risk factor for end-stage renal disease (10, 11). The higher rates of postoperative analgesic requirements, increased atelectasis, pneumonia and venous

thrombosis should be considered along with the higher ~~rates~~incidence of wound complications such as collections and infections. The consequence is a lengthier hospital stay and an increased recovery period. In order to ~~combat~~mitigate these risks whilst expanding the potential live donor pool, established robotic donor nephrectomy from urological practise has been performed in both the live donor and the recipient with equivalent outcomes reported to laparoscopic counterparts (12). Currently the use of robotic donor nephrectomy is limited to centres that are able to afford the equipment and have the infrastructure to support the necessary training required ~~with the new technology~~.

All donors routinely have biochemical assessment of their kidney function, previous or active infections (e.g. serological screening for HBV, HCV, HIV, EBV, HTLV, CMV, Toxoplasma and Treponema) and haematology along with an electrocardiogram (ECG). Urinalysis for protein, blood, leucocytes with appropriate culture and microscopy is routinely undertaken. Outside of these tests, other analyses are performed at the discretion of the investigator depending on baseline results.

During the work up of the donor, it is essential to establish not only the anatomy and the vasculature of the donor kidneys, but also an assessment of the function must be made as well. Given serum creatinine can be influenced by muscle mass, dietary intake and nutritional status, measured glomerular filtration rate (GFR) using a reference GFR procedure is considered more accurate. Pre-donation GFR should be such that the predicted post-donation GFR remains within the gender and age-specific normal range within the donor's lifetime. Further to this, a DMSA or MAG 3 scan assessment of function should also be performed which should give an equal split function across the two kidneys. When renal function is normal but there is a significant (>10%) difference in function between the two kidneys, the kidney with lower function should normally be used for transplantation.

Anatomical anomalies such as cysts or potential tumours should be interrogated with either serial CT or ultrasound scans supported ideally by a specialist radiologist. Once potential malignant lesions are excluded it is then important to establish the vascular anatomy, which can be complex. This enables surgical planning and the anticipation of potential risks in the donor and the need for reconstruction before recipient implantation.

Commented [RMZI]: Somewhere there should be a list of abbreviations spelled out

Most centres prefer to use the left kidney for living kidney donation as the renal vein is longer on this side, which is advantageous during implantation. Nevertheless, a single-centre randomised controlled trial has shown no differences between left- and right-sided donor nephrectomy in hospital stay, quality of life, donor and recipient complication rates, or graft survival (13).

The presence of multiple renal arteries or veins [does](#) not increase the risk of thrombosis or impact short and long-term graft survival (14, 15). Increased rates of urinary leaks have been described in particular when associated with a small polar artery owing to the theoretical supply of ureteric vasculature predominantly from the polar vessel. Multiple renal veins are present in 5-10% of donors (16). Most of the small calibre accessory renal veins can safely be ligated, but occasionally reconstruction to gain length of a short right renal vein maybe necessary.

### ***Recipient***

The initiation of chronic kidney disease and the timing of transplantation can impact on the subsequent patient and graft survival. Pre-emptive (prior to the start of renal replacement therapy), offers a better quality of life for the patient with improved cardiovascular comorbidity risk post transplantation. The timing of transplantation is harder to coordinate in the cadaveric transplant recipient over the live donor. The latter can be organised relatively quickly and the planning of the transplant procedure in line with a more elective surgical procedure. Transplantation of the recipient within 6 months of requiring renal replacement therapy is the ideal standard. The relatively shorter cold and warm ischaemia times, coupled with the healthier donor (due to extensive pre-donation work-up), confer both short and long term survival advantage over the deceased donor counterpart. ~~That being said~~ [Nevertheless](#), not all recipients have this option. Waiting times for patients on the deceased waiting list average at 3 years in the UK and vary according to the recipients ABO blood group and calculated HLA antibody reaction frequency (CRF). It is therefore generally agreed that all recipients should have at least a cursory inquiry into the possibility of a potential live donor at the onset of waiting list assessment. Outcome goals of the assessment of the transplant recipient are listed in **box 1.1**.



GOALS OF THE MULTIDISCIPLINARY RECIPIENT WORKUP

- Ensure transplantation is technically possible;
- Ensure the recipient's chances of survival are not compromised by transplantation;
- Ensure that graft survival is not limited by premature death (maximum benefit obtained from a limited resource)
- Ensure pre-existing conditions are not exacerbated by transplantation
- Identify measures to be taken to minimise peri- and post-operative complications Inform patients of likely risks and benefits of transplantation.

**Box 1.1-** Outcome goals for the kidney transplant recipient, adapted from the UK Renal Association kidney transplant guidelines, 5<sup>th</sup> Edition, 2010.

Even though in most cases, the technical aspects, i.e. the approach and anastomosis of the kidney transplant to the recipient, may be feasible, there are some technical barriers to consider as part of the work up. One of the main considerations is the BMI of the patient. Obesity with a BMI of over 30kg/m<sup>2</sup> carries high rates of peri-operative morbidity (seromas, wound dehiscence, infections, hernias) and generally it is thought that the benefit of transplanting a patient with a BMI >40kg/m<sup>2</sup> is outweighed by the risks (17). Other technical considerations include space for implantation which can be an issue in patients with polycystic kidney disease. Vascular considerations need to be addressed especially when encountering heavily calcified arteries in long standing diabetic recipients. Venous outflow is rarely an issue but previous DVT or a propensity for thrombosis in familial conditions should be addressed appropriately and an anticoagulation plan sought where necessary.

As stated in the summary box 1.1, the medical evaluation of the recipient is a multi-disciplinary process, which focuses on the factors that are likely to influence the safety of the recipient whilst maintaining an optimal outcome for the patient and graft, and thus enables the best utilisation of the donor organ. Identification at the outset of absolute contraindications to transplantation is critical. These ~~include~~ active malignancies, certain active infections, severe ~~uncorrectable-unmodifiable~~ non-renal diseases e.g. cardiac impairment, psychiatric disease that will impact

ability of the patient to adhere to long-term immunosuppression therapy, and active substance abuse. Since the subsequent lifelong immunosuppression to be taken by the recipient will cause a higher risk of malignancy ~~cyt-transformation~~, the assessment of recurrent disease needs to be evaluated. The status of treatments for cervical, bladder, prostate, colonic and skin cancers should be ascertained although outcomes of transplantation after treatment of early stages of these cancers have shown to have good prognoses on registry data (18).

~~Since As~~ the leading cause of death in transplant patients is cardiovascular related disease, the identification of risk factors that can be modified prior to implantation is critical. A basic history should cover management of diabetes, hypertension, smoking, hyperlipidaemia and identify family history risk of coronary artery disease. Perioperative risks are increased with myocardial infarction 6 months prior to surgery, unstable angina, congestive heart failure and the onset of arrhythmias. Even though ~~the~~ routine screening using stress echocardiography and exercise testing can be time consuming and expensive, its use in high risk or symptomatic recipients such as patients with diabetes ~~or patients with a strong family history~~ is warranted to enable safe peri-operative work up and post-operative care. Referral to a cardiology department for treatment of severe coronary artery occlusive disease is mandatory prior to transplantation ~~if required~~.

Commented [RMZ2]: This doesn't make sense – please fix

All sources of bacterial infection should be identified during routine assessment. Areas to be considered include peritoneal catheter sites, dental abscesses, vascular access grafts along with routine urine dipsticks and cultures. Persistent urological infections should be further investigated with pyelography (CT or fluoroscopy) with ultrasound to ensure complete bladder emptying and where necessary cystoscopy.

Routine serology is common practise and recommended by the UK Renal association. This includes viral studies for IgG and IgM titres of cytomegalovirus (CMV), Epstein Barr (EBV), Herpes Simplex (HSV) and Hepatitis and HIV viruses. The use of pan-genotypic direct antiviral agents is likely to mean that Hepatitis B and C

donors are no longer contraindicated to use in non-Hepatitis B and C recipients; at present this practise is not universal.

Assessment of the recipient bladder function can be difficult in the anuric dialysis patient. This is often best left to post-transplantation when kidney function has stabilised. Screening early on in the assessment of elderly (over 60 year old ~~men~~) for prostate disease with a documented digital rectal examination and a serum prostate specific antigen is often all that is required to identify those at risk. Diabetic patients often have neurogenic bladders that should be treated post-transplantation if high residual volumes are discovered after removal of [the urinary catheter](#) post-surgery. Patients with prior cystectomies that have ileal conduits or augmented bladder should be fully investigated with the aid of outpatient CT scans and cystoscopies to delineate the appropriate anatomy prior to listing for transplantation. In this small sub-group of patients, a clear plan for bladder reconstruction or creation of a neocystoureterotomy should be documented.

## Surgical Technique

### *Deceased donor procurement*

Kidney procurement in the context of deceased donation occurs in sequence the other abdominal organs (namely liver and pancreas) in both donation after brain death (DBD) and donation after circulatory death (DCD) donors.

Commented [RMZ3]: ???

There is a distinct warm phase in DBD donors, where-by ~~careful a period of time is spent~~ exposing the inferior vena cava (IVC), left renal vein with mobilization of the duodenum in its entirety superiorly and laterally (Cattell-Braasch manoeuvre), is undertaken. Once key vessels are identified, including the superior mesenteric artery (SMA) caudal to the left renal vein crossing the aorta, the inferior hepatic aorta either at the bifurcation or the common iliac artery can be cannulated to proceed to the cold phase.

The cold phase of procurement is very similar in both DBD and DCD procurement. Unlike DBD, there is no period of warm dissection in DCD and rapid cannulation of the aorta with either IVC or ~~Right-right~~ atrial venting is undertaken through a midline sternotomy and laparotomy. Cross clamping of the aorta in both DBD and DCD procurement can either take place in the supra-coeliac position below the diaphragm, or (as is the authors preference) in the thoracic descending aorta. It is common to wait for 5 minutes in DBD procurement whilst an intravenous bolus of heparin 20-30,000 units is given ~~by the anaesthetist~~ to prevent thrombosis after cross-clamping. In DCD procurement, the cold perfusion fluid is normally heparinised with a similar amount. Optional back table perfusion should be prepared in case once the organs are inspected, perfusion is deemed inadequate.

After cold perfusion of the aorta has commenced, ice slush is applied to both paracolic gutters to commence topical cooling whilst the liver and pancreas are mobilised and removed. It should be noted that the plane between the right lobe of the liver and the right kidney should be dissected through the adrenal gland thus

avoiding kidney or liver capsular injury. Similarly, on the left, a plane close to if not upon the adrenal on the left should be maintained to avoid pancreatic capsular or parenchymal injury.

Mobilisation of the colon should be swiftly undertaken commencing from the ileocolic junction to the descending aspect. Transection of the duodenal-jejunal junction should be performed with a linear stapling device which will allow transection of the small bowel mesentery (again with multiple linear staples if pancreatic procurement is performed). Once this has been performed, the entire small bowel and colon can be exteriorised completely, allowing full view of the abdominal aorta. The left renal vein is then identified and finger swept underneath to allow a cuff of IVC to be taken when transected. Once the SMA is identified and divided at its base, the remaining aorta can be opened and split in the midline. The authors recommend a clean knife blade (size 10) in order to ensure precision in cutting the carrel patch and avoid injury to the renal artery ostia. At this point, the IVC can be divided superior to the right renal vein allowing enough renal vein for the recipient surgeon on both the liver and renal side. This is usually 2 finger breadths (1cm) above the right renal vein.

The right renal ureter is identified first by encircling the peri-ureteric tissue commencing laterally from the psoas to the midline at the level of the right common iliac artery. Care should be taken to avoid removing the peri-ureteric tissue and cause "stripping of the ureter". The ureter should be accompanied by at least 1cm of the peri-ureteral tissues and also the hilar inferior triangle (e.g. the window between the inferior pole of the graft and the ureteral origin from the renal pelvis) should be maintained intact. Once the ureter has been identified, the aortic patch can be mobilised posteriorly maintaining a close plane to the lumbar spine. The right kidney is mobilised by extending the existing plane of dissection towards the psoas, gently pulling the kidney medially. It is possible to apply a haemostat across the ureter at this point and transect the aortic patch and IVC inferiorly, thus releasing the kidney, although it is the authors' preference that both the aorta and IVC are

transected free leaving the kidney on the ureteric pedicle as the last element to be ~~transected~~ divided before the organ is placed immediately on ice to be inspected.

The left kidney is mobilised in a similar manner. The superior plane in the spleno-renal ligament should be carefully transected to avoid traction injury to the pancreas. Mobilisation of the left colon will have already occurred, and it is the authors note of caution to avoid excessive traction of the colon which can lead to inadvertent transection of the left main renal artery or a polar vessel. Retroperitoneal mobilisation is similar to that of the right kidney with transection of the aorta and iliac veins being recommended prior to the ureter.

After placement of the kidneys on ice, the circumferential fat along the lateral aspect of the kidney should be removed as much as possible. This facilitates cooling of the organ whilst equally as importantly allows inspection for lesions, the general state of perfusion and any damage that may have occurred which should be recorded. The organ should then be triple bagged for transport.

## Live Donor Nephrectomy

Living donor kidney transplantation originated in 1954 with the first successful kidney transplant in identical twins by Joseph Murray at the Peter Bent Brigham Hospital. ~~From then on~~ Subsequently, due to the convenience of live donor implants over the logistical ~~difficulties~~ challenges of deceased donors, ~~favoured~~ expansion of transplantation in non-identical twin pairs and then on to related non-twin siblings were favoured. By the mid 1960's and with the pioneering drive of Thomas Starzl, living donor transplantation in the USA was well established. Developmental progress in tissue typing and immunosuppression regimens was made by Paul Terasaki and colleagues to form the basis of modern protocols. It wasn't until 40 years after the first successful kidney transplant, that a major technical step was made in procuring ~~the donor~~ kidneys from live donors.

Commented [RMZ4]: Needs a reference

First described by Ratner in 1995 (19), ~~Laparoscopic~~ laparoscopic donor nephrectomy was a major step in the surgical community in driving living kidney transplantation. This has become the preferred method for procuring kidney grafts from living donors in many centres and accounts for over 70% of the live donor nephrectomies performed in the USA (20). Currently the options for ~~laparoscopic~~ laparoscopic donor nephrectomy are numerous, with both hand assisted and total laparoscopy assisting trans- or retro- peritoneal approaches (Box 1.2).

Given the above work up of the live-donor with appropriate investigations, consent is obtained outlining the risks in the immediate, early and late operative phases. Injury to visceral structures around the kidney should be outlined necessitating the risk of conversion to an open procedure to repair the injury or control any bleeding. This may or may not impact on donation, in which case any event or injury deemed to impact permanently on the health of the donor will cease the process of donation in its entirety.

<i>Surgical techniques for living kidney donation</i>
<b>Open donor nephrectomy technique</b>

<ul style="list-style-type: none"> <li>- Classical flank incision</li> <li>- Muscle-sparing mini-incision donor nephrectomy</li> </ul> <p><b>Laparoscopic transperitoneal technique (*)</b></p> <ul style="list-style-type: none"> <li>- Laparoscopic donor nephrectomy</li> <li>- Hand-assisted laparoscopic donor nephrectomy</li> </ul> <p><b>Endoscopic retroperitoneal technique (*)</b></p> <ul style="list-style-type: none"> <li>- Endoscopic retroperitoneal donor nephrectomy</li> <li>- Hand-assisted Endoscopic retroperitoneal donor nephrectomy</li> </ul> <p><b>* can also be performed with robotic assistance.</b></p>
---

Box 1.2: Techniques in Living donor nephrectomy.

Donor nephrectomy is by convention performed in the lateral decubitus position. Therefore, the donor is warned of the risk of deep vein thrombosis, pulmonary embolus and back pain, with the former requiring the ~~prolonged~~ use of prophylactic low molecular weight heparin for up to 2 weeks post-surgery. In addition to this, the risk of hypertension in the donor should be explained along with the remote risk of developing renal failure in the remaining solitary kidney. Other risks commonly outlined to the donor are listed in Box 1.3.

<p style="text-align: center;"><b>Potential risks of Laparoscopic Donor Nephrectomy</b></p> <p>Mortality range from 1 in 1600 to 1 in 2400  Conversion to open procedure up to 2%  Major risks (up to 5%)</p> <ol style="list-style-type: none"> <li>1. Bleeding</li> <li>2. Visceral injury</li> <li>3. DVT / PE</li> <li>4. Wound infection</li> <li>5. Chest complications- atelectasis, pneumonia</li> <li>6. Urinary tract infection</li> <li>7. Adhesions</li> <li>8. Wound pain, collections; incisional hernia</li> </ol> <p>General Anaesthesia risks  Risks of living with a solitary kidney</p> <ol style="list-style-type: none"> <li>1. Hypertension</li> <li>2. Microscopic Haematuria</li> <li>3. End stage renal disease 0.9% plus requiring the need for renal replacement therapy if remaining kidney is removed for cancer or trauma.</li> </ol>
---



Box 1.3: Common ~~and important~~ ~~ly outline~~ risks associated with Laparoscopic Donor Nephrectomy

Formatted: Left

### ***Laparoscopic Hand Assisted Donor Nephrectomy***

By definition, the removal of a kidney for the purpose of allograft transplantation using both laparoscopy with the placement of a hand is termed laparoscopic hand assisted donor nephrectomy. The ability of a silicone gel hand port enables the hand to be placed in the abdomen without loss of pneumoperitoneum (set at 12-15mmHg). Both retroperitoneal and transperitoneal approaches have been described in the literature with excellent outcomes and acceptability to the donor. Ostensibly transperitoneal laparoscopic donor nephrectomy has been widely adopted over the retroperitoneal [technique](#) in part because most transplant and general surgeons are familiar with peritoneal insufflation and working within the abdomen (20).

With the patient supine, the first port is marked on the skin as the hand port with the authors preference to be drawn just above the pubic symphysis along the “bikini line”. It is ~~generally a point to consider that~~ [ideal for](#) this should [to](#) be drawn to the size of the operator’s hand with the patient asleep, fully relaxed and supine, as the midline of the abdomen may shift during repositioning to the lateral decubitus position. Alternative sites for the hand port include a midline supraumbilical, periumbilical or infraumbilical incision. The hand port can be used partly or totally during the operation. A further 2 ports are introduced - a 12mm port lateral to the umbilicus, and then under vision for the 30° camera, ~~and then~~ a 5mm lateral port for the working instrument ~~of which~~ can be an [used for an](#) energy device or conventional diathermy. For the right kidney, an optional peri-xiphoid 5mm port may be required to help retract the liver. It is usually the authors recommendation that a sleeve be worn to the working arm prior to insertion so that lubricating gel can be applied which facilitates entry into the abdomen and seals any gas leaks as well. The insufflation pressure is set maximally at 12 mmHg.

In the transperitoneal approach, the left or right colon is mobilised along the avascular white line of Toldt towards the pelvis. Gerota's fascia at this point is generally left in place, so that this does not fall and obscure the operators view. In order to expose the renal vein, the fascia overlying the vein is dissected and the renal vein identified. On the left, the adrenal and gonadal tributary is also identified. Gerota's fascia is divided over the adrenal gland at the upper pole extending posterior and inferiorly to the spleen. Mobilisation of the adrenal is preferentially left before complete renal mobilisation as this area can inadvertently bleed.

The ureter and gonadal vein are usually identified inferiorly towards the pelvis and then traced back toward the kidney hilum. Digital sweeping of the tissue laterally with a finger around the gonadal vein and ureter permits mobilisation caudally. With the gonadal vein mobilised at least 2cm away from the renal vein, it is ligated twice with a clip and then divided. This is then repeated in a similar manner for the adrenal vein approximately 1cm at least away from the renal vein. Adequate length of the renal vein on the left side can often be attained without this manoeuvre and should not compromise risk of bleeding from an IVC cuff that retracts after ligation. With ~~any~~ lumbar vessels draining into the renal vein identified and ligated, the renal artery can then be dissected by releasing ~~it~~. The tissue around ~~the base of the renal artery is dissected~~ its base. This can be facilitated by posterior retroperitoneal release of the kidney enabling anterior and posterior views of the renal artery. Once the kidney is mobile in this back and forth motion, the tissue between the renal artery and vein can be divided adequately to ensure passage of the linear cutting endostapling device. Once the ureter is divided with ~~a~~ Hem-o-lok® clips and scissors, the vessels can then be divided. It is the authors preference to use a linear stapler across the renal artery first and then the vein, although it is recognised that Ligaclips and plastic Hem-o-lok® clips have been ~~observed and described~~ utilised in centres outside the UK, with the advantage of millimetres of length gained on the organ vasculature. The counter to this is the catastrophic effect of a potential slip of clips/ligatures with the ensuing morbidity or indeed mortality. Once divided, the mobile kidney can be removed via the hand port and handed to the recipient surgeon on ice to be cold perfused.

Commented [RMZ5]: Worth mentioning a type of stapler?

It is vitally important at this stage to remain focused on the donor with the camera remaining inside to ensure no immediate bleeding. Both staple lines should be inspected after identification, ~~with and haemostasis~~ judicious [haemostasis](#) around the renal bed. The 12 mm port can be closed intracorporally and the Pfannenstiel hand port wound closed in a layered standard fashion with 1 Polydioxanone or Prolene suture ensuring complete closure. It is sometimes advocated in donors with an elevated BMI a closed suction drain applied to the wound to limit the development of seroma, although this observational practise is not supported with high level evidence.

The advantages of hand-assisted laparoscopic donor nephrectomy over full laparoscopy include the ability to use tactile feedback, less kidney traction, rapid control of bleeding, fast kidney removal, less blood loss and shorter warm ischaemic periods (21). The hand port provides additional safety to laparoscopic donor nephrectomy, because rapid control of ~~eventual potential~~ massive blood loss from major blood vessels is possible with hand assistance. The disadvantage includes higher costs ~~because of the associated with a~~ hand port, a worse ergonomic position for the surgeon during the operation, and a higher rate of wound infections.

### ***Laparoscopic Retroperitoneal Donor Nephrectomy***

By far the most common approach to the retroperitoneum for donor nephrectomy is with the use of a hand for assistance (HARS). As previously mentioned, the HARS technique confers the safety advantage by allowing immediate haemostasis should there be a severe sudden bleed. In a pure laparoscopic procedure, sudden severe bleeding from a major vessel is much harder to control and the necessity for open

always  
Other  
listed in

- Advantages of hand assisted and retroperitoneal nephrectomy over total laparoscopic nephrectomy**
1. Port placement- safer with the hand, reduced risk to visceral structures
  2. Control of bleeding- immediate with the hand in [abdominal cavity](#)
  3. Prevention of torsion of the kidney
  4. No risk of internal herniation
  5. Secure/Rapid placement of staplers
  6. Secure/Rapid retrieval of the kidney
  7. Reduction in warm ischaemia time
  8. [Better Shorter](#) learning curve
  9. Reduced risk of bowel obstruction
  10. Reduced risk of adhesions and internal hernias

conversion is  
prioritised.  
advantages are  
Box 1.4

Box 1.4: Advantages of Hand assisted retroperitoneal donor nephrectomy

### ***Fully Laparoscopic Donor Nephrectomy***

Without the tactile sensation of the hand inside the abdomen, the approach to the fully laparoscopic donor nephrectomy is slightly more technically challenging than its hand assisted counterpart and has a steeper learning curve. ~~Handling of~~ [theDissection of](#) tissues is of critical importance and vigilance must be taken on both the retracting forceps as well as the working energy device dissection.

Port placement is again user dependant, but the authors agree on the common placement of a subxiphoid 5mm port, a periumbilical 12 port, a lateral 12mm port and a lower Pfannenstiel incision similar to the hand port of the hand assisted approach, [measuring](#) approximately 6-8cm in diameter and [lying](#) approximately 1-2cm above the pubic symphysis centred over the midline.

Mobilisation of the colon is performed in a similar fashion to [that](#) previously stated, with medial visceral rotation carefully performed to identify the ureter whilst separating the mesocolon from the mesoureteral structures in the avascular plane.

Identification of the ureter and dissection laterally over the psoas, enables caudal mobilisation towards the renal pelvis and the kidney. In a similar manner to the hand assisted approach, careful identification of the gonadal and adrenal tributaries from the renal vein should be undertaken, with the former being traced from the ureteric

pedicle. As previously stated, dissection around the hilum and identification of the renal artery can take place once the vein is in clear view. The adrenal vein tributary at the superior aspect of the renal vein can be isolated with a right-angled dissector, ligated and clipped before being transected.

It is the authors' preference to identify the plane between the adrenal and the kidney and dissect close to the adrenal gland with electrocautery. Once the adrenal gland is separated, mobilisation towards the spleen can then take place with division of the splenorenal ligament using a Ligasure or similar device. The upper pole of the kidney will be fully mobile now, ~~and with the remaining fat~~ between the vessels remainings to be dissected. The latteris should be done with great care so as not to cause traction injury to the renal artery. Once the posterior retroperitoneal attachments to the kidney are released and the vessels mobilised, ~~stapling of the renal stapling~~ artery ~~and then followed by the~~ vein, in a similar manner to the hand assisted approach, can take place. An Endo Catch™

is inserted via the lower abdominal Pfannenstiel incision, with care taken to maintain the pneumoperitoneum by creating a purse string suture in the peritoneum before the instrument enters the abdominal cavity. Once the Endo Catch™ is removed with the kidney, the purse string can be pulled close to enable inspection of the renal bed for haemostasis along with identification of the staple lines.

### ***Open Retroperitoneal Nephrectomy***

In the era of laparoscopy, the open donor nephrectomy operation in the developed world has become largely historical. Having been the standard from 1954 until the mid 1990s, the operation is still performed in a minimal access manner in limited numbers, but has largely been replaced with the previously described minimally invasive techniques. Laparoscopic donor nephrectomy is associated with a significantly shorter hospital stay, fewer postoperative analgesic requirements, improved cosmetic appearance and a quicker return to work as compared with open donor nephrectomy and ~~results in~~ similar allograft function (22). The slight disadvantage of the laparoscopic technique is that it results in a shorter vascular

pedicle when compared with the open donor nephrectomy. The warm ischaemia time and operating time for laparoscopic donor nephrectomy is also substantially longer than compared with open donor nephrectomy. A 2008 meta-analysis of 4 randomised control trials comparing laparoscopic ~~donor nephrectomy~~ with open donor nephrectomy found no significant difference in post-operative complications, although longer warm ischaemia times were noted in [the laparoscopic studies with the former](#) (22).

With the patient positioned in the lateral decubitus position, an incision is conventionally made between the anterior superior iliac spine and the 12<sup>th</sup> rib anterior to the mid axillary line. Resection of the distal part of the lowest rib can be applied to allow sufficient access to the kidney. Dissection and division of the latissimus dorsi, external oblique, internal oblique and transversus abdominus muscles should occur with exposure of the peritoneum which can then be swept medially to enter into the retroperitoneum. Judicious retraction is required at this point to expose Gerota's fascia which can be divided to enable [sweeping towards exposure of](#) the kidney hilum. Once the perinephric fat is divided, the vessels can be easily identified and isolated with a vessel sling. The adrenal gland can be bluntly dissected with a finger with cautious use of electrocautery to ensure minimal bleeding. Once the vessels are isolated [and](#), the tributaries ligated, adequate artery and vein length should be obtained in order to pass a haemostat across their respective bases. The vascular pedicles are oversewn with 5-0 Prolene each. Once divided, the ureter can be identified on its pedicle and transected with adequate length using a Hem-o-lok® clip and scissors.

With one of the most common post-operative complications from open nephrectomy being incisional hernias, judicious haemostasis and layered closure should take place in a systematic and precise fashion. Each muscle layer is closed with a 1 Polydioxanone suture and the deep dermal layer approximated with 3-0 Vicryl absorbable suture. It is not the authors preference to leave a drain unless there is an absolute necessity or the risk of seroma formation [is high](#) e.g. in high BMI (>35kg/m<sup>2</sup>) patients.

### **Robotic Donor Nephrectomy**

~~The use of~~ robotic surgery in donor nephrectomy was first reported in 2002 (23). Use of ~~the a~~ multi-armed, multi-port instrument with the operating surgeon ~~unscrubbed~~ in a separate operating module is now widely established in urological practise. The application in transplantation not only in donor nephrectomy but also in recipient implantation has gained much momentum over the last decade with leading centres in India and the USA publishing case series (24). The potential advantages sought over conventional laparoscopy lies in the optics and dexterity the arms of the robotic instruments can provide.

The donor nephrectomy is performed with the patient in a decubitus position. Four trocars are placed in the left or right side of the abdomen to allow placement of three articulated robotic arms, the robotic camera, and the standard laparoscopic instruments used for retraction and dissection during the procedure.

The limitation of laparoscopic instruments is their inability to articulate fine dissection of hilar vessels in a confined space. This is where the use of the small multi-faceted robotic arms ~~excel~~ excels. Proponents of the technique, claim the advantageous potential to create vascular exposure and increase length of vessels, whilst reducing the time for such dissection in the skilled operators hands, although the authors find limited evidence to this. Whether this level of finesse impacts on graft outcome is again not evidenced. Currently for many units the high costs of the machine and consumables makes the technology a non-essential commodity. Nonetheless despite longer operating times and warm ischaemia, post-operative pain requirements are reportedly reduced in donors without impact on immediate function (12, 24).

Commented [RMZ6]: Needs rephrasing!

## **Complications**

Both laparoscopic and open donor nephrectomy operations have significant operative risks that should be outlined at the time of ~~listing and~~ consenting. Registry data has found that the mean stay after laparoscopic donor nephrectomy to be approximately 2.5 days with the quoted overall complication rate to be between 6-8%, whereas for open nephrectomy the mean length of stay is 5 days with an overall quoted complication rate of 2% (22). The 90-day mortality rate after laparoscopic and open nephrectomy is 0.03% and 0.04% respectively (25). The main significant difference is the return to work and normal activity, which is on average 6 weeks post laparoscopy and can be up to 3 months following open donation. Major complications (Clavien grade  $\geq 3$ ), are rare, ranging from 3 to 6% ~~after~~ (26, 27), with the overall rate of morbidity significantly higher after open donor nephrectomy compared to laparoscopic nephrectomy (28).

One of the most important potential risks is the development of end stage renal disease (ESRD) following kidney donation and has been quoted as low as 0.9% over 15 years (6, 7). Even though this risk remains higher, however, than matched non-donor counterparts, ~~it-but~~ remains much less than that of the general (unscreened) population. Compared to the general public, kidney donors have equivalent (or better) survival, excellent quality of life, and no increase in ESRD. Certain patient groups (e.g. black donors, younger donors, genetically related donors, donors to patients with immunological causes of renal failure, and overweight donors) have a higher risk of ESRD following donation (6, 7, 29).

For the recipient, the benefits of living, compared to deceased-donor, kidney transplantation are well known with most donors also enjoying a quality of life that is similar or even better when compared with the general population (30, 31). These results are linked to the intense medical evaluation of potential ~~living kidney~~ donors, resulting in the selection of only healthy and motivated individuals. Several studies have reported a better quality of life of donors after laparoscopic donor nephrectomy than after open donor nephrectomy, and in terms of costs, although



laparoscopic donor nephrectomy has the potential to be more expensive due to the use of disposable instruments, ~~several studies have demonstrated~~ better cost-effectiveness [has been found](#) compared with open donor nephrectomy (32-35).

## Recipient implantation

The basic operative methodology for renal transplantation has changed little from the principles of vascular anastomosis described by Alexis Carrel in 1902 and subsequently revised by René Küss and colleagues in 1951 (18, 36). Preparation and preservation of the kidney is essential to maximise early and late graft function after transplantation and is achieved in part through the use of preservation solutions and maintaining the graft in hypothermic conditions.

Three approaches exist with regard to the surgical placement of the renal allograft: 1) extraperitoneal, 2) transperitoneal, and 3) intraperitoneal. Traditionally implantation has been extraperitoneal in the right iliac fossa for renal transplantation alone or a simultaneous liver-kidney transplant owing to the superficial position of the external iliac vein and ease of graft assessment by palpation, auscultation and biopsy. Alternatively, the left iliac fossa can be used to allow the pancreas to be on the right side in a simultaneous pancreas-kidney transplant, with pancreas exocrine drainage ~~controlled by anastomosis to~~ the small bowel or bladder and endocrine release into the systemic or portal venous circulatory system. A transperitoneal approach may be used following failed kidney transplants in both iliac fossae and the intraperitoneal approach in small children to accommodate the relatively large graft. Morbidity associated with an intraperitoneal approach remains higher than ~~the extraperitoneal one~~ with complications such as visceral injury or bowel obstruction and adhesions almost exclusively observed in the former (37). In the case of dual kidney transplantation (DKT) these are often split for individual implantation either ipsilaterally or bilaterally in the iliac fossae of the recipient via a classic Rutherford ~~morrison-Morrison~~ incision and will be discussed in more detail below.

### **Implantation site**

As alluded to above, the classical site for renal transplantation is the right iliac fossa, centred over the external iliac vasculature, as the longer and more horizontal right external iliac vessels facilitate easier vascular anastomoses. However, the advantage of placing the donor kidney in the recipient's contralateral side ensures the renal pelvis and ureter lie anterior and will be easier to access should the need arise for further surgeries (e.g. ureteric reconstruction). Other factors to consider when deciding on the site of surgery include previous surgery (e.g. including failed renal transplantation), severe atherosclerotic/calcific disease affecting iliac arteries, pelvic exploration and peritoneal dialysis catheters and are further outlined in Table 1. The use of both internal iliac arteries in serial renal transplantations in men is avoided to prevent impotence (38). Large grafts have historically been implanted within the abdominal cavity so as to prevent potential "kidney compartment" syndrome (over compression of the renal parenchyma limiting venous outflow). However it is the authors preference to still place the large kidney allograft into the iliac fossa but use either a subrectus pouch to position the kidney, a mesh to enable fascial closure without compression or use the right iliac retroperitoneal space to permit aortic anastomosis or common iliac artery with venous drainage either to the inferior vena cava or common iliac vein.

**Table 1: Factors to take into consideration for implantation site.**

<b>Factor</b>	<b>Preferred Site</b>	<b>Explanation</b>
Previous surgeries	Opposite iliac fossa	Prevention of visceral/vessel injury or lymphocele and shorter operative time
Multivisceral operation	Left iliac fossa in the retroperitoneal space Abdominal cavity for en bloc paediatric transplantation	Prevention of complications spreading from one graft to another
Size/length/number of graft arteries and veins	Iliac fossa	Prevention of postoperative ileus
Size/length/number of ureters	Iliac fossa if recipient ureter not diseased	Prevention of urine leakage or ureteral stricture

Number of kidney grafts	Retroperitoneal space of right iliac fossa	In this case it is better may be better to use the abdominal aorta and inferior vena cava
Anomalies of donor graft	Abdominal cavity/iliac fossa depending on size of graft	Space consideration for graft and anastomotic sites for graft vessels/ureters

Historically, the three incisions used for renal transplantation are the Gibson incision, the 'hockey stick' incision and the Rutherford Morrison oblique incision. The Gibson incision is the most common approach and involves a relatively atraumatic curvilinear incision that starts two centimetres medially to the anterior superior iliac spine, running 0.5 centimetres above the inguinal fold, and is continued to the lateral border of the rectus muscle. The para-rectus 'hockey stick' incision is prolonged medially to the midline above the pubic symphysis and can be extended upward to the subcostal margin. One advantage of this approach is that it yields better access to the common iliac vessels and inferior vena cava. Its disadvantages include denervation of the para-rectal groove, lesser strength of the wall closure, and potentially inferior cosmetic appearance due to its direction against the Langer skin lines. Although shorter in length, the oblique incision may require the division of all the lateral abdominal muscles. Nanni and colleagues compared the 'hockey stick' and oblique incisions for post-operative complications and concluded that the latter was [better for associated with a reduced](#) incidence of hernias and more favourable cosmetically (39). Whichever approach is used, it is imperative that all incisions are accompanied by strict haemostasis to avoid wound or peri-graft haematomas that could eventually lead to infection, dehiscence, hydronephrosis or kidney compartment syndrome from compression of the graft.

Mobilization of a length of the external iliac vessels is conducted (and common iliac arteries is also needed when the internal iliac artery is considered as the candidate of arterial anastomosis). Exposure of the iliac vessels requires precise technique to avoid peritoneal injury and subsequent enterocele, commonly described as a 'renal paratransplant hernia'. In addition, post-renal transplant lymphoceles resulting from [poor inadequate](#) lymphatic ligation can result in unnecessary patient morbidity. One

study that followed up the impact of surgical technique on the incidence of lymphoceles. ~~It was~~ reported that thorough ligation of all lymphatics using silk ties, both during dissection of the recipient vessels and the donor allograft, significantly ~~reduced~~ reduces the incidence of this complication (with one patient in their series of 273 transplants developing a lymphocele)(40).

Following iliac vessel mobilization, the process of vascular anastomosis ~~may~~ begins after choosing suitable points of vascular inflow and outflow along the iliac vessels. The site of each anastomosis and the position of the graft should be specified accurately according to the size and length of the vessels and also the length of the ureter and position of the recipient bladder. The kidney graft is placed in the wound and the renal vessels stretched to the recipient vessels to determine the best sites for the arterial and venous anastomoses. After confirming the exact length and position of the anastomosis site to prevent donor vessel kinking or rotation, vascular clamps are applied to the recipient vessels. We prefer to use Statinsky clamps for side-clamping of the external iliac vein or inferior vena cava and angled Dardik clamps to the common or external iliac artery.

It is important the anastomosis steps are completed carefully but in a timely manner as the kidney lies outside the body (i.e. out of cold storage) for this process, thus theoretically presenting an opportunity for graft insult. The classical technique involves end-to-side venous anastomosis first, followed by an end-to-side arterial anastomosis.

### ***Venous Anastomoses***

Classically, allograft vein to the recipient iliac vein is anastomosed in an end-to-side fashion using a continuous monofilament suture (5-0 or 6-0 Prolene). The venous valve site in the external iliac vein should be avoided, if possible, as the wall of the vein is very thin proximal to the venous valves (sinuses of Valsalva) and may be ruptured during the anastomosis. The length of the donor vein can be increased by refashioning the inferior vena cava cuff which may be of particular importance in a

short right renal vein (Figure 1). Saphenous, gonadal or superficial femoral vein grafts as well as polytetrafluoroethylene grafts have also been used to successfully elongate short donor veins. Venous reconstruction is probably best avoided when using kidneys with prolonged cold ischemic times and from DCD donors, to avoid the risk of venous thrombosis. Any reconstructions of the donor vein should take place prior to implantation of the kidney and, as mentioned below, excessive elongation should be avoided to protect against renal vein kinking and thrombosis; this is particular true for the left renal vein which is invariably shortened.

Commented [RMZ7]: Any reference for this?

Initial sutures are placed either end of the venotomy with an anchor suture sometimes placed at the mid-point of the lateral wall to prevent the anterior or posterior wall being caught up in the suture line. The anchoring sutures can prevent posterior wall suturing whilst ensuring end-to-side apposition.

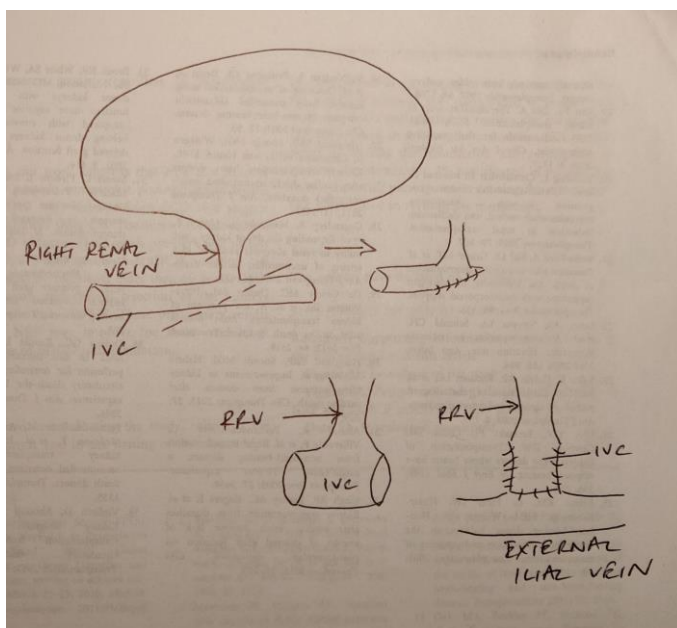


Figure 1: Venous extension of a right renal vein can be performed either with an oblique transection of the IVC or side oversew of the IVC ends.

Inaccessible or unsuitable iliac veins in the recipient can be managed by using the infrarenal and infra-hepatic inferior vena cava. In rare cases where both the iliac veins and the inferior vena cava have thrombosed, satisfactory results have been achieved with anastomosis of the renal vein to the portal venous drainage system, inferior and superior mesenteric veins and even large venous collaterals such as the left ovarian vein.

### ***Arterial Anastomoses***

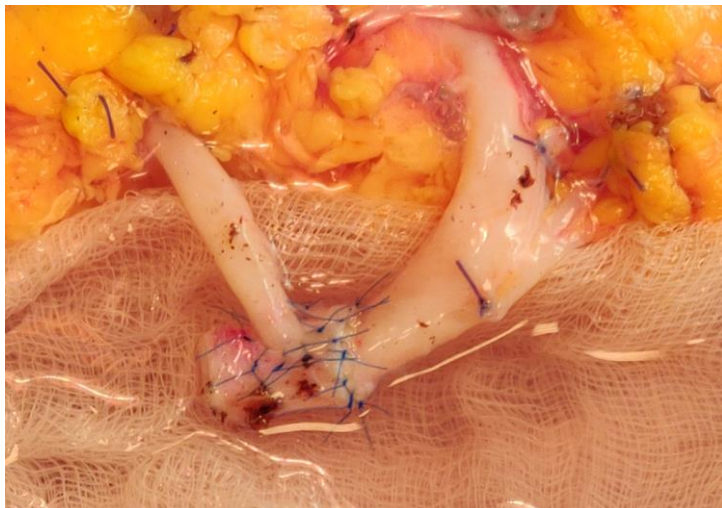
Most operators would agree that surgical equipoise dictates personal preference over evidence base for renal artery to donor vessel anastomosis. Using a monofilament suture (5-0, 6-0 or 7-0), the most common vessel for end-to-side anastomosis is the external iliac artery (EIA), which is generally placed at a point more proximally than the vein, and for end-to-end anastomosis the internal iliac artery (IIA) in both living and deceased donor transplants [remains the best option](#).

The external iliac artery is incised longitudinally and the lumen is irrigated with heparinized saline. An opening of a suitably-sized calibre created with an artery puncher is created in the common or external iliac artery and facilitates the anastomosis of renal arteries from live donors in the absence of Carrel patch. An endarterectomy is not needed in most cases, but if it is performed, any intimal flaps must be completely secured to the arterial wall with a tagging U-stitch. Taking full-thickness sutures of the arterial wall, particularly in patients with arteriosclerosis, must be meticulous to complete the anastomosis. The needle should move from inside to outside of the more diseased artery (usually the recipient artery) to tag the intima to the media of the artery and prevent creating of an intimal flap, and potential thrombosis.

If a deceased donor graft has multiple vessels a Carrel patch of aorta and inferior vena cava in line with the graft vessels can be used, although the latter may be limited to the right kidney only. The patch technique, however, may result in elongated donor vessels (artery on the right side and vein on the left side) that

leaves the graft vulnerable to a compression kink and could be a site of stenosis, thrombosis or hypertension at a later post-operative follow up. Dual arteries on a single patch to a right-sided kidney often make positioning of the kidney difficult without kinking one or the other artery ~~if both arteries~~, and might necessitate dividing the patch and shortening the arteries to fulfil two separate anastomoses. In addition, the Carrel patch may be severely atherosclerotic and might not be suitable for a safe anastomosis.

Multiple renal arteries in a living related donor represent more of a challenge. It is considered acceptable to ligate smaller arteries (less than one millimetre) of the upper and middle pole depending on the supply to the renal cortex. This can be judged during preservation perfusion of the kidney immediately after retrieval or after perfusion by the main donor vessel. Ligation is usually considered acceptable if the dependant area is judged to be less than 10%. Arteries bigger than one millimetre should be anastomosed to the EIA or even the inferior epigastric artery following reperfusion of the graft, especially in the lower pole to avoid ischaemia of the ureter. Smaller vessels (one to five millimetres) ~~are generally~~ can be anastomosed using an interrupted monofilament (Prolene) suture that ensures an even distribution of tension around the vessel and prevents ~~ing~~ theoretical stricturing that can be caused with a continuous suture. In the living donor recipient setting, it is also the authors' experience to isolate a section of the ~~distal internal iliac artery~~ IIA down towards the first branches and utilise the end for an end-to-end anastomosis with the main renal artery and then an end-to-side of the polar vessel directly onto the conduit ~~(Fig 2)~~ or end-to-end with one of the first-order branches. Once the reconstruction has been performed on the back table, the internal iliac end can be anastomosed back together with interrupted Prolene in an end-to-end fashion to the proximal IIA. The use of the internal iliac saves prolonged clamping of the EIA and leg ischaemia whilst preserving future options for the external iliac to be used.



**Figure 2: Use of the internal iliac artery conduit to create an end to end anastomosis of the main renal artery and end to side of the lower polar vessel. Interrupted 6-0 prolene sutures placed. Picture courtesy of Mr N Russell, Cambridge.**

Variant anatomy with two or more renal arteries may be anastomosed together side-to-side preserving the lumen of each vessel, or anastomosed separately to either the recipient EIA, IIA or one renal branch to each.



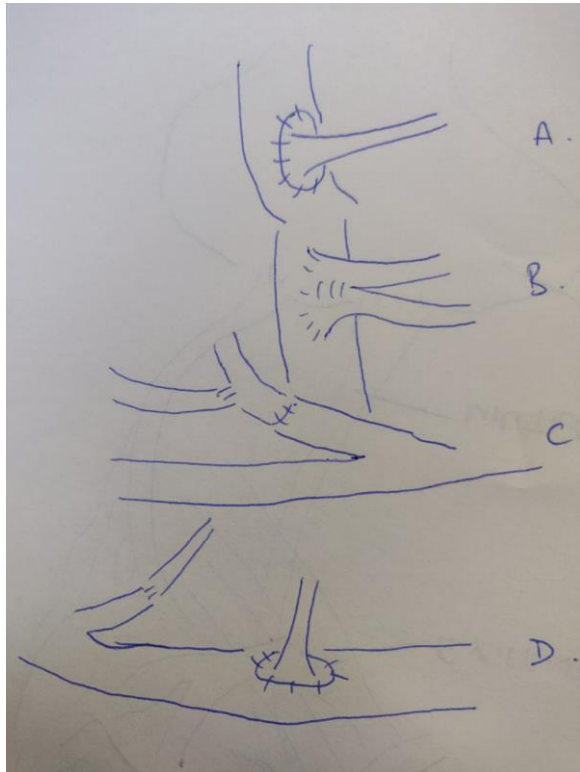


Figure 3: Some of the variant arterial anastomotic techniques. A- standard end to side anastomosis with the Carrel patch, B- trouser side to side of 2 vessels with an end to side anastomosis to the external iliac artery, C- end to [end](#) of the internal iliac with main artery and an end to side of the polar vessel to the artery, D- use of the inferior epigastric artery for a lower polar artery.

Different techniques may be employed if a surgeon attempts to reconstruct arteries before implantation including side-to-side anastomosis of same size arteries or end-to-side anastomosis of a smaller artery to a larger one (Figure 3). In situations where the renal artery is damaged the best approach it is to transect the diseased part and use a small branch of the donor artery (for example, the donor iliac artery) as an elongation conduit of the renal artery. However, this would inevitably prolong the operative time and thus impact the length of warm ischaemia of the kidney.

### **Reperfusion**

At the point of completion of the vascular anastomosis, vessel clamps can be removed to aid in reperfusion. It is the authors practise ~~to~~[for reperfusion to coincide with](#) ~~at~~ a mean arterial pressure (MAP) of at least 65 with a systolic blood pressure of between 110 to 120mmHg. At this point, the kidney is inspected for [fullness of](#) perfusion and then felt globally to ensure the organ is adequately filled. A soft kidney may be indicative of under filling or even arterial inflow problems, whereas an overly tense kidney could be a sign of venous outflow compromise. It is recommended that constant communication is held with the anaesthetist during the peri-reperfusion period so that changes in cardiovascular status is known and managed appropriately. Potential challenges can occur with a non-perfused kidney and a pulsatile hilum indicative of thrombosis or occlusion. At this point preparation should be made to reclamp the iliac vessels, cold perfuse the organ [with preservation solution](#) and refashion the anastomoses. Preparation for blood loss should be made and it may be useful to consider cell salvage of blood. Intraoperative ultrasound can also be used to check flow within the artery and vein if doubt exists on the perfusion of the kidney, which may be the case in prolonged cold stored organs.

### ***Ureteric Implantation***

The most common early post-operative complication in renal allograft transplantation (ranging from quoted rates of 5 to 10%) arises from the vesicoureteric anastomosis (37). Two complications are recognised: urinary leak and ureteral stenosis. Prevention of these begins with meticulous attention to the surgical technique.

Urinary tract reconstruction begins following successful reperfusion of the donor kidney with the type of reconstruction dependent on the position of the graft, condition of the recipient's bladder (or bladder alternative) and the length, condition and number of donor ureters. The most commonly employed technique is the ureteroneocystostomy (UNC) and is often categorised into transvesical or extravesical procedures. It is the authors' preference to keep the ureter as short as is feasible for a comfortable anastomosis to prevent distal ureteric ischaemia.

Maintenance of the lower polar triangle of ureteric mesentery is essential given that blood supply to the upper ureter is originated from the lower polar arterial branches.

The Leadbetter-Politano approach (transvesical UNC) utilises one anterior cystostomy to access the interior of the bladder and a posterior cystostomy to recreate a new ureteric orifice in the normal anatomical position with the ureter subsequently tunnelled in the submucosa to prevent reflux. Murray et al exploited this method during their first successful human renal transplant in 1954 (41). The Lich-Gregoir technique (extravesical UNC) was first published in 1961 where the aim was to avoid a second cystostomy but maintain comparable antireflux mechanisms (41, 42). The procedure consists of a suprahialal detrusor myotomy and exposure of the bladder mucosa. Using either continuous or interrupted sutures the ureter is anastomosed to the mucosa [with PDS II \(polydioxanone\) suture](#) and then the detrusor muscle closed over it. Advantages compared to its counterpart procedure involve less bladder dissection, a shorter ureteral length and, overall, a quicker operative time associated with reduced morbidity.

A further variation of the extravesical approach to UNC includes the U-stitch technique where after creating the antireflux tunnel (following dissection of the detrusor muscle and incision of the bladder mucosa), only one U-stitch at the toe or two U-stitches at the toe and the heel of the ureter are used to anchor it before closing with the detrusor muscle. This method can leave the anastomosis vulnerable to leakage, however, especially when there is concern about the distal ureteric blood supply and risk to ischaemia. Alternatively, two parallel incisions in the detrusor muscle may be used: one to transfer the ureter in a submucosal tunnel and the second to anastomose the ureter to the ureteral mucosa. Finally, the ureter may also be anastomosed to the full-thickness wall of the bladder without any antireflux mechanism.

Most surgeons use a ureteral stent to reduce the risk of obstruction in the post-operative period if the ureter or bladder tissue appears marginal. A meta-analysis

evaluated five prospective, randomised, controlled ~~clinical~~ trials of routine stenting following renal transplantation and indicated that the collective urinary complication rate following routine stenting was 1.5% compared to 9% without stenting (43). The markedly lowered incidence of ureteric complications, often a cause of graft loss, appeared to outweigh any increased risk of stent-associated problems such as urinary tract infections or bladder spasms. However, cystoscopic stent removal in the early period post transplantation (between two and six weeks) is ~~important~~ imperative in order to avoid complications such as haematuria, stone formation and infection. Recent technological developments have ~~found their place-enabled post-operative stent removal~~ in the outpatient setting, with disposable instruments such as the Isiris™ (Coloplast, Humlebaek, Denmark) endoscope complete with an incorporated camera module and grasper for the sole purpose of stent extraction. The solitary high cost of the single use camera is offset for the need of theatre space and a day surgery bed with conventional cystoscopy. Another innovation removes the need for cystoscopy altogether with the ability to connect a magnet incorporated on the stent with that on the tip of a disposable catheter. The Magnetic Black Star retrieval catheter (Urotech, Achenmühle, Germany) is an introducer catheter smaller than a conventional urinary catheter and designed for the sole purpose of retrieving the stent with the magnet in a single procedure ~~that can be performed again in the outpatient setting~~. Unlike the Isiris system, no prior endoscopic experience is necessary and as such could be performed by a range of healthcare professionals.

In the case of a substandard graft ureter (too short, ischaemic or devascularised), or difficulty mobilising the bladder to enable a sufficient anastomosis, use of the native ureters may be necessary if there is clear lack of evidence for stricture, dilatation, reflux or infection. The surgeon may therefore perform an ureteroureterostomy, pyeloureterostomy or even pyeloneocystostomy. In rare cases where the renal transplant ureter and native ureter are both unsuitable, a pyelovesicostomy may be completed. Ureteral duplication is the most common congenital malformation of the urinary tract but there are few cases in the literature that describe renal transplantation with completely duplicated ureters. Bozkurt and colleagues used a

modified extravesical UNC technique on a cadaveric kidney transplant with a completely duplicated ureter (44). The distal ends of the duplicated ureters were spatulated and their medial ends approximated before the distal parts were anastomosed to form a single cuff and subsequently sutured to the mucosa of the bladder. This approach differed to the previously described procedure involving anastomosis of both distal ends of the ureters to each other followed by the Lich-Gregoir technique for UNC.

### **Wound closure**

Given the potential morbidity associated with wound collections and dehiscence, judicious care should be taken when closing the kidney transplant wound. Mass closure can be adopted, although ~~it is the authors suggestions that~~ particular care ~~must be~~ taken in the upper lateral aspects of the external and internal oblique aponeurosis opposition to prevent ~~later~~ incisional herniation. Meticulous technique at the time of closure is the best form of defence. A large silicon drain is commonly used which can be removed in the first few post operative days and this has the added advantage of reducing lymph collections immediately post operatively whilst being a safety measure for urinary leak should they occur.

### **Multiple Graft Implantation**

In the current climate of growing transplant waiting lists and a shortage of organ donors, the use of extended criteria donors (ECD) is set to gain further momentum in the short term future (45). ~~Extended criteria donors are considered those kidneys from older (over 65 years) patients, have pre existing comorbidities (such as hypertension, diabetes and ischaemic heart disease) and are usually, but not exclusively, from DCD donors.~~

Commented [RMZ8]: This is not the real definition of ECD!

Outcomes of transplants from ECD are associated with higher rates of acute rejection episodes and long-term graft dysfunction (46). However, a benefit of extra life-years is still observed in recipients when compared to dialysis patients on the waiting list. Clinical characteristics that marginalise such donors include age, a

history of hypertension or diabetes, the risk of transmitting infection or malignancy, brain death versus cardiac death, the presence of graft abnormalities as well as the morphology and functioning profile of the kidney.

One option for using organs from donors with a suboptimal nephron mass is dual kidney transplantation (DKT). This involves the simultaneous transplantation of two marginal kidneys from donors older than 60 years old or from a solitary paediatric patient younger than five years old or less than 21 kilograms in size. When retrieved from paediatric patients the two kidneys are transplanted en-bloc and the aorta and inferior vena cava anastomosed to the external iliac artery and vein in an end-to-side technique.

Dual kidneys from older donors are mostly split for individual implantation either ipsilaterally or bilaterally in the iliac fossae of the recipient. Outcomes have been of dual kidneys from standard and extended criteria donors were reported with success by Remuzzi et al (47, 48) with the now established clinical pathology scoring system for clinical decision making. A unilateral DKT is performed via a classic Gibson incision is made, preferably on the right side. The right kidney is placed superiorly as its renal vein may be lengthened by a segment of inferior vena cava. If necessary the internal iliac vein can be divided to facilitate anastomosis of the renal vein to it and the renal artery anastomosed to the external iliac artery. Vascular clamps are placed immediately below the arterial and venous anastomoses following revascularisation of the right kidney; ~~and~~ the left kidney is then implanted inferomedially and anastomosed also to the external iliac vessels. Extravesical ureteroneocystostomies are then performed separately leaving the ureter of the upper transplanted kidney lateral to the lower one.

The utilisation of elderly ECD kidneys in DKT use has been controversial. The development of a UK national pathology service to analyse biopsies is the aim of the recently commenced PITHIA trial (49). It is predicted that each transplant unit's acceptance of kidneys for transplantation from elderly donors will increase by 10%.

Commented [RMZ9]: This makes no sense!

with the availability of a 24 hour pathology service that will risk predict the quality of the donor kidney based on the Remuzzi score (47, 48).

## Complications of Renal transplantation

### **Wound complications**

Wound complications post kidney transplantation is by far the most common cause of morbidity with a reported incidence of around 5% (1, 37). Risk factors associated with the development of wound issues can be categorised into patient related and drug related. Patient related factors include obesity, diabetes, clotting or pre-existing haematological disorders. The most common drug to cause wound problems in the immediate-early post-operative period is Sirolimus which has been associated with lymphocoele accumulation as well as dehiscence (50). Diagnosis is largely clinical with local pain, erythema, discharge and dehiscence being common complaints. Closure with skin clips enables local drainage of collections and the application of a superficial vacuum assisted closure (VAC) system. ~~It is the authors experience to use superficial vacuum drains in large subcutaneous spaces to prevent the accumulation of seromas, although the evidence for this is limited.~~ Treatment of wound infections with antibiotics should be guided based on positive microbiological cultures. Complete full thickness dehiscence of the wound is rare, but mandates return to theatre, wound washout and vacuum-assisted closure. Repeated exploration of patients for recurrent seromas or haematomas may give rise to the risk of incisional hernias which ~~could~~ can be managed with mesh repair in the context of culture negative microbiology.

### **Arterial**

Post-transplantation transplant renal artery stenosis (TRAS), is not uncommon with the varied reported rates of incidence in part attributed to lack of standardised definition of haemodynamically significant transplant renal artery stenosis. They can cause significant morbidity with transplant dysfunction and even failure.

Commented [RMZ10]: What is the range of incidence?

The aetiology is complex with multiple predisposing factors such as pre-existing atherosclerosis, arterial trauma/ischaemic during transplant, cytomegalovirus infection and surgical technique. Transplant renal artery stenosis may arise in the donor renal artery, surgical anastomotic site or in the recipient iliac artery secondary to surgical trauma (51).

Initial evaluation of TRAS is most commonly performed ~~with-by~~ colour flow duplex ultrasound, with Magnetic resonance angiography (MRA) preserved for those with potentially complex vascular anatomy. Significant vascular stenosis is ~~determined suggested~~ by Doppler findings of: (i) peak systolic velocities > 200cm/second, (ii) velocity gradient between stenotic and prestenotic segment of >2:1, and (iii) distal turbulence seen as spectral ~~broadening~~.

Commented [RMZ11]: Parvus tardus waveform

Institutions adopt varying intervention management strategies, with some performing percutaneous angioplasty (PTA) ~~and~~ solely reserving stents for balloon-resistant stenoses (52) ~~over-stenting~~ as the primary percutaneous intervention. Primary angioplasty is often implemented in those with stenosis affecting the main-stem or first-order segmental arteries, whilst stent placement is performed in case of residual stenosis or dissection (53).

A meta-analysis reported a higher technical success (98% vs 77%), lower restenosis rate (17% vs 26%) and clinical outcome (20% vs 10% cure rate in hypertension, and 30 vs 38% improvement rate of renal function,  $p < 0.001$ ) in stent placement compared to angioplasty alone (54).

Conservative management of TRAS has a higher risk of graft failure (65%) with early intervention (52). Medical management is advocated if the stenosis is considered haemodynamically insignificant or if intervention is considered associated with high risk of graft loss.

~~In a~~ retrospective single centre study of 44 primary angioplasty treated ~~transplant renal artery stenoses~~TRAS, ~~82-81%~~ demonstrated improvement in graft function,



with this cohort being the only one illustrating both significant and sustained improvement in BP and serum creatinine, compared to groups treated with surgery or conservative medical management (52).

Surgery is reserved for those refractory or with unfavourable anatomy for PTA. Other indications for surgery include recent transplant, multiple stenoses, long and narrow stenoses (52).

### ***Venous***

Venous thrombosis is relatively rare but a clinically devastating post-operative complication (2.9% in one study of 103 renal transplants (41), with quotes of ranging from 0.5% to 4% (37)). It should be considered in the presence of acute severe suprapubic swelling or sudden onset frank haematuria (42) and is most common within the first 30 days post-operatively. Even though there are many intrinsic causes of thrombosis, it is more likely that in the immediate post-operative setting the cause is due to kinking of the renal vein or the onset of sustained hypotension. Of note, numerous retrospective studies have found that intraoperative heparin did not reduce the incidence of graft thrombosis(43)(44)(45). Despite some solitary case reports of thrombolysis, the usual treatment of choice is graft salvage with a reoperation and thrombectomy and re-anastomosis. The choice of anticoagulation post operatively will be balanced against the risk of bleeding or collections, but it is the authors experience that haematomas and collections are easier to manage than subsequent thrombotic episodes.

**Commented [RMZ12]:** In most cases, graft thrombosis necessitates nephrectomy

### ***Ureteric complications***

Despite the widespread use of intraoperative placement of transplant ureteric stents, the reported ureteric complication rate is widely quoted from 2-4% (1). Ureteric complications are largely leak related or obstructive (stenosis or external compression from, for example, a lymphocoele). Clinical evidence of a leak can be in the form of suprapubic or graft site tenderness in the setting of oliguria or with a differentially high drain creatinine. The cause of this in the immediate post

operative setting is either technical or necrosis due to an ischaemic ureter. Management of leaks is almost always surgical correction, although temporising ureteric stents can be placed in the context of minor leaks.

A longer term complication in the setting of insidious graft dysfunction and sonographic features of hydronephrosis, is ureteric stenosis. This can occur over several weeks to months and can be associated with infection, ischaemia or rejection (55, 56). Initial management must confirm the absence of infection, temporising urinary drainage with a percutaneous nephrostomy prior to definitive treatment. This is either with balloon ureteroplasty for short segment stenosis or surgical reimplantation of the ureter. The latter can be performed directly back on to the bladder itself or implanting the native ureter onto the transplant pelvic ureteric junction in the case of lengthy stenotic lesions.

### ***Lymphocoele formation***

The disruption of lymphatics either during dissection of the iliac vasculature in the recipient or during procurement of the kidney and preparation of the renal hilum, can cause collections of lymph post-operatively. Documented incidence of lymphocoeles range from 0.6 to 18% making it one of the most common causes of morbidity in the post operative renal transplant recipient (57, 58). Diagnosis is based on graft dysfunction with the presence of a collection surrounding classically the lower pole of the kidney on sonography. Aspiration of the collection can confirm the lymphocoele when sent for biochemistry ~~and has the same analysis as plasma~~. Management can be either percutaneous or open drainage, with fenestration of the peritoneum under open or laparoscopic vision. This should be performed with judicious balance towards drainage of the lymph in a sizeable window without risking the development of intestinal herniation. Excellent results have been seen with laparoscopic approaches to lymph drainage compared to open (58). Another option is the injection of a sclerosant such as iodine, tetracycline or fibrin glue, although mixed outcomes of complete resolution have been reported (58).

## Discussion

Kidney transplantation has become the gold standard operation for patients with end-stage renal disease. Early recognition and management of post-operative complications is key to minimising patient morbidity, and potentially mortality, attributed to graft loss. This review has attempted to summarise the foundations upon which the surgical procedure is based as well as highlight current discussions within the literature surrounding potential updates to these techniques.

Variation in surgical implantation site has evolved with the advent of multivisceral procedures and the inclusion of suboptimal grafts. Thoughtful consideration must be given to the use of kidneys from extended criteria donors (ECD) and the implementation of dual kidney transplantation (DKT) as both are associated with a [higher](#) risk of inferior outcome when compared to a standard kidney transplant. ~~Additionally, the use of sutureless anastomotic techniques to reduce warm ischaemia time of the graft potentially warrants further investigation, as initial work appeared promising.~~ Finally, a consensus is required regarding intraoperative heparin infusion to avoid peri- or post-operative thrombosis as recent evidence suggests little to no benefit over no infusion.

Of course, not to be overlooked is the development, advancement and clinical integration of robotic technology in renal transplant surgery. The first case report of laparoscopic kidney transplantation was published in 2010 demonstrating the feasibility of such a procedure; however, operative anastomosis time was slower when compared in other studies with open kidney transplantation(59). Nevertheless, limited published data report less pain, better cosmetic appearance, fewer wound complications resulting in shorter hospital stay, and equivocal graft function to an open procedure at one month post-transplant. It is clear that with refinement of laparoscopic devices and technique this is a strategy may be widely employed in the near future. The current limitation of high cost with an equivocal outcome measure over conventional laparoscopy means uptake is likely to be slow, ~~therefore as the technique progresses time will tell whether superiority in patient~~

[outcomes develops with benefits potentially to be seen in sub-group of patients e.g. those with high BMI.](#)

[You should write also a small section on perfusion techniques – cold \(e.g. Lifeport\), ex-vivo warm blood perfusion etc](#)

## References

1. A.A Klein CJL, J.C Madsen. Organ Transplantation; A Clinical guide. Cambridge University Press, 2011.
2. Libby P, Pober JS. Chronic rejection. *Immunity* 2001;14(4):387-397.
3. Pascual M, Theruvath T, Kawai T, Tolkoff-Rubin N, Cosimi AB. Strategies to improve long-term outcomes after renal transplantation. *N Engl J Med* 2002;346(8):580-590.
4. Heaphy EL, Poggio ED, Flechner SM, Goldfarb DA, Askar M, Fatica R et al. Risk factors for retransplant kidney recipients: relisting and outcomes from patients' primary transplant. *Am J Transplant* 2014;14(6):1356-1367.
5. Nankivell BJ, Borrows RJ, Fung CL, O'Connell PJ, Allen RD, Chapman JR. The natural history of chronic allograft nephropathy. *N Engl J Med* 2003;349(24):2326-2333.
6. Muzaale AD, Massie AB, Wang MC, Montgomery RA, McBride MA, Wainright JL et al. Risk of end-stage renal disease following live kidney donation. *JAMA* 2014;311(6):579-586.
7. Mjoen G, Hallan S, Hartmann A, Foss A, Midtvedt K, Oyen O et al. Long-term risks for kidney donors. *Kidney Int* 2014;86(1):162-167.
8. Matas AJ, Wadstrom J, Ibrahim HN. Kidney donation and risk of ESRD. *JAMA* 2014;312(1):92-93.
9. Heimbach JK, Taler SJ, Prieto M, Cosio FG, Textor SC, Kudva YC et al. Obesity in living kidney donors: clinical characteristics and outcomes in the era of laparoscopic donor nephrectomy. *Am J Transplant* 2005;5(5):1057-1064.
10. Kalantar-Zadeh K, Kopple JD. Body mass index and risk for end-stage renal disease. *Ann Intern Med* 2006;144(9):701; author reply 701-702.
11. Vivante A, Golan E, Tzur D, Leiba A, Tirosh A, Skorecki K et al. Body mass index in 1.2 million adolescents and risk for end-stage renal disease. *Arch Intern Med* 2012;172(21):1644-1650.
12. Yang A, Barman N, Chin E, Herron D, Arvelakis A, LaPointe Rudow D et al. Robotic-assisted vs. laparoscopic donor nephrectomy: a retrospective comparison of perioperative course and postoperative outcome after 1 year. *J Robot Surg* 2018;12(2):343-350.

13. Minnee RC, Bemelman WA, Maartense S, Bemelman FJ, Gouma DJ, Idu MM. Left or right kidney in hand-assisted donor nephrectomy? A randomized controlled trial. *Transplantation* 2008;85(2):203-208.
14. Hsu TH, Su L, Ratner LE, Trock BJ, Kavoussi LR. Impact of renal artery multiplicity on outcomes of renal donors and recipients in laparoscopic donor nephrectomy. *Urology* 2003;61(2):323-327.
15. Saidi R, Kawai T, Kennealey P, Tsouflas G, Elias N, Hertl M et al. Living donor kidney transplantation with multiple arteries: recent increase in modern era of laparoscopic donor nephrectomy. *Arch Surg* 2009;144(5):472-475.
16. Gerstenkorn C, Papalois VE, Thomusch O, Maxwell AP, Hakim N. Surgical management of multiple donor veins in renal transplantation. *Int Surg* 2006;91(6):345-347.
17. Tran MH, Foster CE, Kalantar-Zadeh K, Ichii H. Kidney transplantation in obese patients. *World J Transplant* 2016;6(1):135-143.
18. Rahul Koushik BK. Chapter 16: Kidney Transplantation- The Recipient. Mc Graw Hill Medical, 2008.
19. Ratner LE, Ciseck LJ, Moore RG, Cigarroa FG, Kaufman HS, Kavoussi LR. Laparoscopic live donor nephrectomy. *Transplantation* 1995;60(9):1047-1049.
20. Anand Khakar RV, Lloyd E Ratner. Chapter 15 Kidney Transplantation: The Donor. Mc Graw Hill Medical, 2008.
21. Kokkinos C, Nanidis T, Antcliffe D, Darzi AW, Tekkis P, Papalois V. Comparison of laparoscopic versus hand-assisted live donor nephrectomy. *Transplantation* 2007;83(1):41-47.
22. Nanidis TG, Antcliffe D, Kokkinos C, Borysiewicz CA, Darzi AW, Tekkis PP et al. Laparoscopic versus open live donor nephrectomy in renal transplantation: a meta-analysis. *Ann Surg* 2008;247(1):58-70.
23. Horgan S, Vanuno D, Sileri P, Cicalese L, Benedetti E. Robotic-assisted laparoscopic donor nephrectomy for kidney transplantation. *Transplantation* 2002;73(9):1474-1479.
24. Giacomoni A, Di Sandro S, Lauterio A, Concone G, Buscemi V, Rossetti O et al. Robotic nephrectomy for living donation: surgical technique and literature systematic review. *Am J Surg* 2016;211(6):1135-1142.
25. Segev DL, Muzaale AD, Caffo BS, Mehta SH, Singer AL, Taranto SE et al. Perioperative mortality and long-term survival following live kidney donation. *JAMA* 2010;303(10):959-966.
26. Patel S, Cassuto J, Orloff M, Tsouflas G, Zand M, Kashyap R et al. Minimizing morbidity of organ donation: analysis of factors for perioperative complications after living-donor nephrectomy in the United States. *Transplantation* 2008;85(4):561-565.
27. Mjoen G, Oyen O, Holdaas H, Midtvedt K, Line PD. Morbidity and mortality in 1022 consecutive living donor nephrectomies: benefits of a living donor registry. *Transplantation* 2009;88(11):1273-1279.
28. Hadjianastassiou VG, Johnson RJ, Rudge CJ, Mamode N. 2509 living donor nephrectomies, morbidity and mortality, including the UK introduction of laparoscopic donor surgery. *Am J Transplant* 2007;7(11):2532-2537.
29. Ibrahim HN, Foley R, Tan L, Rogers T, Bailey RF, Guo H et al. Long-term consequences of kidney donation. *N Engl J Med* 2009;360(5):459-469.

30. Clemens KK, Thiessen-Philbrook H, Parikh CR, Yang RC, Karley ML, Boudville N et al. Psychosocial health of living kidney donors: a systematic review. *Am J Transplant* 2006;6(12):2965-2977.
31. Smith GC, Trauer T, Kerr PG, Chadban SJ. Prospective psychosocial monitoring of living kidney donors using the Short Form-36 health survey: results at 12 months. *Transplantation* 2004;78(9):1384-1389.
32. Andersen MH, Mathisen L, Veenstra M, Oyen O, Edwin B, Digernes R et al. Quality of life after randomization to laparoscopic versus open living donor nephrectomy: long-term follow-up. *Transplantation* 2007;84(1):64-69.
33. Perry KT, Freedland SJ, Hu JC, Phelan MW, Kristo B, Gritsch AH et al. Quality of life, pain and return to normal activities following laparoscopic donor nephrectomy versus open mini-incision donor nephrectomy. *J Urol* 2003;169(6):2018-2021.
34. Buell JF, Lee L, Martin JE, Dake NA, Cavanaugh TM, Hanaway MJ et al. Laparoscopic donor nephrectomy vs. open live donor nephrectomy: a quality of life and functional study. *Clin Transplant* 2005;19(1):102-109.
35. Nicholson ML, Elwell R, Kaushik M, Bagul A, Hosgood SA. Health-related quality of life after living donor nephrectomy: a randomized controlled trial of laparoscopic versus open nephrectomy. *Transplantation* 2011;91(4):457-461.
36. PJ. M. Transplantation--a medical miracle of the 20th century. *N Engl J Med* 2004;23(351(26)):2.
37. Ferreira M dAM, Tucci S. . Surgical Complications of Renal Transplantation.
38. Gittes RF, Waters WB. Sexual impotence: the overlooked complication of a second renal transplant. *J Urol* 1979;121(6):719-720.
39. Nanni G, Tondolo V, Citterio F, Romagnoli J, Borgetti M, Boldrini G et al. Comparison of oblique versus hockey-stick surgical incision for kidney transplantation. *Transplant Proc* 2005;37(6):2479-2481.
40. Khan T. Post Kidney Transplant Lymphoceles: Meticulous Ligation of Lymphatics Reduces Incidence. 2011.
41. Baston C HM, Preda A, Gener I, Manea I, Voinea S, et al. . Comparative urologic complications of ureteroneocystostomy in kidney transplantation: transvesical Leadbetter-Politano versus extravesical Lich-Gregoir technique. *Transplant Proc* 2014 46(1):3.
42. Zilinska Z CM, Trebaticky B, Breza J, Slobodnik L, Breza J, et al. . Vascular complications after renal transplantation. *Bratisl Lekárske Listy* 2010;111((11)):3.
43. Mangus RS HB. Stented versus nonstented extravesical ureteroneocystostomy in renal transplantation: a metaanalysis. *Am J Transplant* 2004;4(11):7.
44. MT. BB. Modified Extravesical Ureteroneocystostomy in Cadaveric Kidney Transplantation with Completely Duplicated Ureters: A Case Report. *J Transplant Technol Res* 2014 04 (2).
45. NHSBT. Taking Organ Transplantation to 2020. In: England N, (ed). Bristol: NHSBT, 2018.
46. Lucarelli G, Bettocchi C, Battaglia M, Impedovo SV, Vavallo A, Grandaliano G et al. Extended criteria donor kidney transplantation: comparative outcome analysis between single versus double kidney transplantation at 5 years. *Transplantation Proceedings* 2010;42(4):1104-1107.

47. Remuzzi G, Grinyo J, Ruggenti P, Beatini M, Cole EH, Milford EL et al. Early experience with dual kidney transplantation in adults using expanded donor criteria. Double Kidney Transplant Group (DKG). *J Am Soc Nephrol* 1999;10(12):2591-2598.
48. Remuzzi G, Ruggenti P. Renal transplantation: single or dual for donors aging > or =60 years? *Transplantation* 2000;69(10):2000-2001.
49. G P. <http://www.pithia.org.uk>. 2016; Available from:
50. Schaffer M, Schier R, Napirei M, Michalski S, Traska T, Viebahn R. Sirolimus impairs wound healing. *Langenbecks Arch Surg* 2007;392(3):297-303.
51. Kobayashi K CM, Rossman LL, Kyriakides PN, Kahan BD, Cohen AM. . Interventional radiologic management of renal transplant dysfunction: indications, limitations, and technical considerations. . *Radiographics* 2007 Jul-Aug;;27(4).
52. Ghazanfar A TA, Augustine T, Pararajasingam R, Riad H, Chalmers N. . Management of transplant renal artery stenosis and its impact on long-term allograft survival: a single-centre experience. . *Nephrol Dial Transplant* 2011 Jan;26(1):7.
53. Voiculescu A SM, Hollenbeck M, Braasch S, Luther B, Sandmann W, Jung G, Mödder U, Grabensee B. . Management of arterial stenosis affecting kidney graft perfusion: a single-centre study in 53 patients. . *Am J Transplant* 2005 Jul;;5((7)):7.
54. Leertouwer TC GE, Bosch JL, van Jaarsveld BC, van Dijk LC, Deinum J, Man In 't Veld AJ. . Stent placement for renal arterial stenosis: where do we stand? A meta-analysis. . *Radiology* 2000 Ju;l; 216(1):7.
55. Baig MA, Khan T, Mousa D. Post transplant ureteric stenosis causing allograft hydronephrosis and calyceal rupture: salvage side to side ureteroneocystostomy. *Saudi J Kidney Dis Transpl* 2010;21(3):504-506.
56. Keller H, Noldge G, Wilms H, Kirste G. Incidence, diagnosis, and treatment of ureteric stenosis in 1298 renal transplant patients. *Transpl Int* 1994;7(4):253-257.
57. Golriz M, Klauss M, Zeier M, Mehrabi A. Prevention and management of lymphocele formation following kidney transplantation. *Transplant Rev (Orlando)* 2017;31(2):100-105.
58. Lucewicz A, Wong G, Lam VW, Hawthorne WJ, Allen R, Craig JC et al. Management of primary symptomatic lymphocele after kidney transplantation: a systematic review. *Transplantation* 2011;92(6):663-673.
59. Wagenaar S, Nederhoed JH, Hoksbergen AWJ, Bonjer HJ, Wisselink W, van Ramshorst GH. Minimally Invasive, Laparoscopic, and Robotic-assisted Techniques Versus Open Techniques for Kidney Transplant Recipients: A Systematic Review. *Eur Urol* 2017;72(2):205-217.